

FINAL ANSWER KEY

Question 31/2024/OL

Paper Code:

Category 348/2023

Code:

Exam: Assistant Professor in Paediatrics

Date of Test 23-03-2024

Department Medical Education

Question1:-During embryogenesis, which of the following cells do not differentiate from neuro ectoderm

A:-Neuron

B:-Astrocyte

C:-Oligodendrocytes

D:-Microglia

Correct Answer:- Option-D

Question2:-Which of the following statements regarding growth and hormonal control of a child are true ?

i. Foetal growth depends mainly on insulin and insulin-like growth factors

ii. Infant growth according to Infant Child Puberty Model (ICP) is mainly by growth hormone

iii. Child growth depends mainly on nutrition and environment

iv. Pubertal growth depends on sex hormone

A:-Statement i and iv are correct

B:-All statements are correct

C:-Statements i, ii and iii are correct

D:-Statements ii, iii, iv are correct

Correct Answer:- Option-A

Question3:-Correct statement regarding Bone Age (BA) assessment is

A:-Well spread right hand and wrist X-ray exposing all digits is used for Bone Age assessment

B:-Greulich-Pyle atlas is the most accurate for BA assessment

C:-In Tanner Whitehouse II method, 13 bones are taken, given score and is common for both sexes

D:-Gilsanz-Ratib atlas is a digital atlas and is easy to interpret

Correct Answer:- Option-D

Question4:-Of the statements on pathogenesis of obesity, which one is false ?

A:-Hormone leptin is synthesised from hypothalamus and increased in obesity

B:-Ghrelins synthesised from stomach stimulate appetite

C:-Adiponectins produced from fat tissues is reduced in obesity

D:-Melanocortin 4 receptor gene mutation is the most common genetic cause of obesity

Correct Answer:- Option-A

Question5:-Which of the following statements regarding dyslexia is/are correct ?

i. Dyslexia is the most common specific learning disability.

ii. Males are more commonly affected than females.

iii. Functional MRI findings in dyslexia are :

anterior Broca's area is normal while two posterior areas, word analysis and word

forming areas, are abnormal.

iv. In dyslexic children there is developmental uncoupling between reading IQ (Intelligence

Quotient) and true IQ.

A:-All are correct

B:-i, ii, iii are correct

C:-i, iii, iv are correct

D:-Only iv correct

Correct Answer:- Option-C

Question6:-Which of the following statements regarding growth charts is correct ?

A:-First designed by Michel Gordon

B:-Fenton charts are used in preterm children, till 56 weeks

C:-WHO multicentric growth reference study is used till 18 years

D:-In growth charts-3 SD corresponds 0.13 percentile

Correct Answer:- Option-D

Question7:-Which of the following statements regarding adolescents with mental health problems is false ?

A:-Delusion of grandiosity is a specific symptom of mania

B:-One of the diagnostic criteria for Bulimia nervosa is Body Mass Index less than 13 kg/m²

C:-Anhedonia is a core symptom of depression

D:-The clinical features of anorexia nervosa are lanugo hair, swollen parotid and dental erosion

Correct Answer:-**Question Cancelled**

Question8:-The most common test for assessing Intelligence Quotient (IQ) after three years

A:-Bayley scale for infant development

B:-Wechsler's intelligence scale for children

C:-Stanford Vinet intelligence scale

D:-Vineland Adaptive behaviour scale

Correct Answer:- Option-B

Question9:-With regards to development of a child, which of the following statements are correct ?

- i. Child attains object permanence by 9 months.
- ii. The mature sleep pattern in EEG is attained usually by 4-6 months.
- iii. Child can count four pennies correctly by 5 years.
- iv. Child can identify four primary colours correctly by three years.

A:-Statements i and ii are correct

B:-Statements iii and iv are correct

C:-Statements ii, iii, iv are correct

D:-Statements i, ii, iii are correct

Correct Answer:- Option-A

Question10:-Which of the following sleep disorders is a predominant Rapid Eye Movement (REM) sleep event ?

A:-Nightmare

B:-Somnambulism

C:-Sleep terror

D:-Confusional arousal

Correct Answer:- Option-A

Question11:-Regarding fatty acid composition in the diet, which of the following statements is false ?

A:-Diet should contain at least 3% of fat as essential fatty acid

B:-The optimum ratio of omega 3 is omega 6 fatty acid in the diet should be 10:1

C:-Decosahexanoic acid (DHA) synthesised from alpha Linolenic acid is important for retinal function

D:-Linoleic acid is converted to arachidonic acid in the body which is important for platelet function

Correct Answer:- Option-B

Question12:-Which of the parameters is not included in Global Hunger Index ?

A:-Stunting

B:-Oedema

C:-Wasting

D:-Mortality

Correct Answer:- Option-B

Question13:-Which of the following statements regarding rickets is correct ?

i. 1, 25-dihydroxycholecalciferol is elevated in type II vitamin D dependent rickets.

ii. The earliest sign of clinical rickets is widening of wrists.

iii. For the prevention of rickets, it is essential to have sunlight exposure with wavelength of 280-320 nm.

iv. FGF 23 is a humoral mediator that increases proximal tubular reabsorption of

phosphorus.

A:-All are correct

B:-i and ii are correct

C:-i, ii and iii are correct

D:-i, iii, iv are correct

Correct Answer:- Option-C

Question14:-Which of the following statements regarding fluid electrolyte balance is not correct ?

A:-Regulation of plasma osmolality is maintained by water balance

B:-Regulation of plasma volume is controlled by vasopressin

C:-Renin secretion is regulated by perfusion pressure in afferent arterioles

D:-Atrial natriuretic peptide increases sodium reabsorption in medullary collecting system

Correct Answer:- Option-D

Question15:-Which statement is wrong with regards to SIADH ?

A:-It is a condition with euvolemic hyponatremia

B:-Urine osmolality is more than 100 mOsmol/kg, which is more than plasma osmolality

C:-Renal, adrenal and thyroid insufficiency are to be ruled out before diagnosis'

D:-Urinary sodium is less than 30 mEq/L with corresponding serum sodium less than 135 mEq/L

Correct Answer:- Option-D

Question16:-4 year old boy presented with history of Diabetic ketoacidosis with serum sodium 126 mEq/L, serum potassium 2.4 mEq/L and pH 6.34 and serum bicarbonate⁻4 mEq/L. Child was treated with insulin infusion and fluid management. Child developed seizure and deterioration of sensorium with confusion on day 2. Clinical examination showed spastic quadriparesis. What is the most common diagnosis ?

A:-Central pontine myelinolysis

B:-Associated encephalitis

C:-Intra cranial haemorrhage

D:-Water intoxication

Correct Answer:- Option-A

Question17:-Which is not a feature of Gordon's syndrome ?

A:-Autosomal dominant inheritance

B:-Hypertension is a very prominent clinical finding

C:-It is also called Pseudo-hypoaldosteronism Type 1

D:-Hyperkalemic metabolic acidosis is an associated finding

Correct Answer:- Option-C

Question18:-Mechanism of action of Orlistat

A:-Sympathomimetic action on hypothalamus

B:-Serotonin agonist

C:-Pancreatic lipase inhibitor

D:-GABA receptor modulation

Correct Answer:- Option-C

Question19:-Gold standard investigation for diagnosis of acute appendicitis in a child

A:-Ultrasonography

B:-Complete blood counts with differential count

C:-Laparoscopy

D:-CT scan abdomen

Correct Answer:- Option-D

Question20:-GI endoscopy showing multiple aphthous ulcers with normal background in small intestine is characteristically seen in which condition ?

A:-Intestinal lymphangiectasis

B:-Ulcerative colitis

C:-Crohn's disease

D:-Alpha-1 anti-trypsin deficiency

Correct Answer:- Option-C

Question21:-SGOT more than SGPT is seen in all of the following conditions except

A:-Alcoholic hepatitis

B:-Fulminant echo virus infection

C:-Wilson's diseases

D:-Paracetamol toxicity

Correct Answer:- Option-D

Question22:-Alpha feto protein is elevated in all of the following conditions except

A:-Reye's syndrome

B:-Hepatoma

C:-Hepatoblastoma

D:-Hereditary tyrosinemia

Correct Answer:- Option-A

Question23:-What is the gene mutation associated with Watson-Alagille syndrome ?

A:-JAG 1 mutation

B:-CYP 7B1 mutation

C:-ABCB4 mutation

D:-ABCB11 mutation

Correct Answer:- Option-A

Question24:-Which statement regarding neonatal hemochromatosis is wrong ?

A:-Marked elevation of SGOT and SGPT are present till late in diseases

B:-It is a gestational allo-immune disease

C:-Liver cell shows decreased hepcidin expression

D:-Buccal mucosal biopsy is diagnostic

Correct Answer:- Option-A

Question25:-In which of the following conditions Serum Albumin to Ascitic Albumin Gradient (SAG) is >1.1 ?

A:-Cirrhosis liver

B:-Budd-chiari syndrome

C:-Nephrotic syndrome

D:-Cardiac failure

Correct Answer:-**Question Cancelled**

Question26:-All are features of single gene disorder except

A:-Phenotypes can vary from one patient to another

B:-They tend to occur when changes in gene have profound effect on the quantity of gene product produced

C:-They will not have variable expressivity

D:-They can be caused by de novo sequence changes that are not found in the unaffected parents

Correct Answer:- Option-C

Question27:-Genetic testing is interpreted by all the factors except

A:-Analytical validity

B:-Analytical utility

C:-Clinical utility

D:-Clinical validity

Correct Answer:- Option-B

Question28:-Choose the correct statement about Achondroplasia

A:-Autosomal recessive inheritance

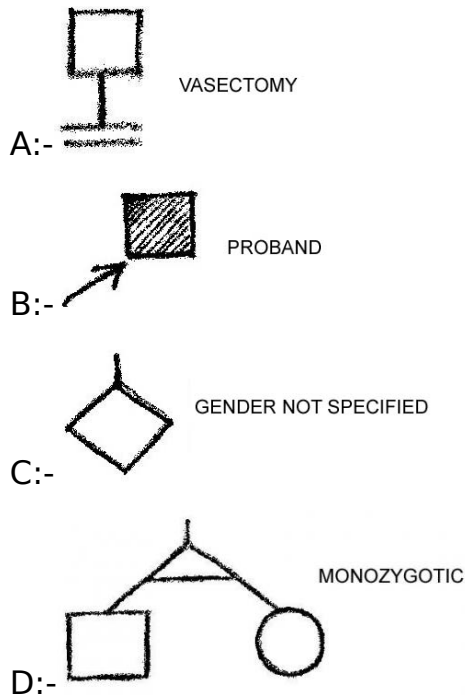
B:-Result from mutation of FGFR4 receptor gene

C:-Is an example of Gain of function variant type of inheritance

D:-None of the above

Correct Answer:- Option-C

Question29:-Which of the following illustration is wrong ?



Correct Answer:-**Question Cancelled**

Question30:-A child is brought to you with visual defect and a diagnosis of Retinitis Pigmentosa is confirmed. Both parents have normal vision. This is an example for

- A:-Pseudogenetic inheritance
- B:-Mosaicism
- C:-Non-traditional inheritance
- D:-Digenetic inheritance

Correct Answer:- Option-D

Question31:-The peculiar odor of urine in Tyrosinemia-type-1 is

- A:-Rancid butter
- B:-Cats urine
- C:-Mousey urine
- D:-Acrid

Correct Answer:- Option-A

Question32:-Which of the following deficiency can present as acquired hypertyrosinemia ?

- A:-Vitamin A
- B:-Selenium
- C:-Vitamin C
- D:-Pyridoxine

Correct Answer:- Option-C

Question33:-Intravenous Arginine infusion is benefitted in all the following except

- A:-Citrullinemia

B:-OTC deficiency

C:-HHH syndrome

D:-Arginase deficiency

Correct Answer:- Option-D

Question34:-The main circulating form of Pyridoxine is

A:-Pyridoxal 5' phosphate

B:-Pyridoxal 1' phosphate

C:-Pyridoxamine

D:-Pyridoxal 6' phosphate

Correct Answer:- Option-A

Question35:-All are true about Canavan disease except

A:-Caused by deficiency of Aspartoacylase

B:-Autosomal Recessive inheritance

C:-Causes Leukodystrophy

D:-Defective gene is located on Chromosome 18

Correct Answer:- Option-D

Question36:-Which of the following statement is false ?

A:-Amniotic Fluid Index more than 24 cm is suggestive of Polyhydramnios

B:-Amniotic fluid volume increases at a steady rate up to 40 weeks

C:-Amniotic fluid volume is less than 10 ml at 8 weeks

D:-Amniotic Fluid Index less than 5 cm is suggestive of Oligohydramnios

Correct Answer:- Option-B

Question37:-Choose the incorrect statement.

A:-Presence of acceleration in fetal heart rate monitoring indicates absence of Fetal Acidemia

B:-Variable deceleration occur with umbilical cord compression are slow in onset and resolution and will occur with uterine contractions

C:-Early decelerations are a physiological vagal response to uterine contractions

D:-Late decelerations are associated with fetal hypoxia

Correct Answer:- Option-B

Question38:-A fetus is subjected for Ultrasonographic evaluation. You are requested to give expert opinion based on the USG Report. Choose the wrong advice.

A:-Dilated ventriculomegaly more than 10 mm. Most likely possibility is Hydrocephalus. Need postnatal Evaluation like MRI

B:-Echogenic Bowel. The incidence is 0.6 percentage. Likely to be normal. Need only follow up

C:-Thickened nuchal fold. Suggestive of Syndrome. Need postnatal evaluation

D:-Dilated renal Pelvis. The incidence is 0.6 percentage. Can be normal.
Repeat USG should be done within 7 days

Correct Answer:-**Question Cancelled**

Question39:-Which of the following statement is false ?

A:-Placental vascular anastomoses occur with high frequency in Monochorionic twins

B:-Acardiac Fetus is secondary to the twin reversed arterial perfusion syndrome

C:-Maternal polyhydramnios in twin pregnancy suggest twin to twin transfusion

D:-Twin to twin transfusion syndrome is more common in dizygotic twins

Correct Answer:- Option-D

Question40:-A five year old boy is brought to you with Hemiparesis, seizures and cognitive delay. There is history of birth asphyxia. The most likely area of injury in the newborn period is likely to be

A:-Selective neuronal necrosis

B:-Parasagittal injury

C:-Focal ischemic necrosis

D:-Periventricular injury

Correct Answer:- Option-C

Question41:-Which is the correct sequence in the development of heart involving the following structures ?

1. Formation of septum primum.

2. Muscular ventricular septum.

3. A-V Valves.

4. Ostium secundum.

A:-1-2-3-4

B:-4-3-2-1

C:-1-4-2-3

D:-4-1-2-3

Correct Answer:- Option-A

Question42:-Total fetal cardiac output is approximately

A:-400 ml/kg/min.

B:-450 ml/kg/min.

C:-480 ml/kg/min.

D:-510 ml/kg/min.

Correct Answer:- Option-B

Question43:-All the statements are true except

A:-T wave in V1 lead should never be positive before 6 years of age

B:-Pediatric ECG recording should include additional leads like V3R and V4R

C:-Mean QRS axis of newborn is in the range of +110 to +180 degree

D:-Children less than 4 years will have R:S ratio less than 1 in V4R

Correct Answer:- Option-D

Question44:-Which of the following statement is true ?

A:-Membraneous VSD is more likely to close than small muscular VSD

B:-Aortic regurgitation is more likely to develop as a complication in infracristal VSD

C:-Presence of Left atrial and left ventricular volume overload indicates that the Qp:Qs is greater than 2:1

D:-VSD is called as restrictive when the size is less than 4 mm.

Correct Answer:- Option-C

Question45:-Pathologic ECHO findings in Rheumatic Mitral regurgitation include all the following except

A:-Seen in at least 2 views

B:-Peak velocity is more than 2mt/sec

C:-Pan systolic jet is seen in at least 1 envelope

D:-Jet length is equal to or more than 2 cm in at least 1 view

Correct Answer:- Option-B

Question46:-Select the true statement.

A:-Restrictive cardiomyopathy is characterized by significantly dilated cardiac chambers

B:-Hypertrophic cardiomyopathy is characterized by myocyte dystrophy

C:-Pathology in dilated cardiomyopathy is myocyte hypertrophy and scattered fibrosis

D:-Arrhythmogenic right ventricular cardiomyopathy is characterized by islands of fatty replacement and fibrosis

Correct Answer:- Option-D

Question47:-All are false statements about Milrinone except

A:-Mechanism of action is inhibition of phosphodiesterase

B:-Very rare to cause hypotension

C:-Not recommended for children awaiting cardiac transplant

D:-Has positive inotropic effect on heart and peripheral vasoconstrictive effect

Correct Answer:- Option-A

Question48:-Choose the wrong match.

A:-Wischot-Aldrish syndrome-Leukemia

B:-Noonan syndrome-Osteosarcoma

C:-Bloom syndrome-Lymphoma

D:-Neurofibromatosis-2-Meningoma

Correct Answer:- Option-B

Question49:-All the following are indication for performing Micturating cystourethrography in children with UTI as per ISPN consensus guidelines except

A:-Non-E. Coli UTI in <2 years of age

B:-E. Coli UTI in Infancy

C:-Recurrent UTI

D:-Bilateral hydronephrosis in male child

Correct Answer:- Option-B

Question50:-A neonate presents with clinical features of failure to thrive, hypokalemia and metabolic alkalosis. The baby also has transient hyperkalemia and nephrocalcinosis. Which of the following genetic defect is the child most likely to have ?

A:-CLCNKB

B:-SLC12A1

C:-KCNJ1

D:-BSND

Correct Answer:- Option-C

Question51:-Which of the following is the most common cause of atypical Hemolytic uremic syndrome in Indian children and adolescents ?

A:-Anti-factor H antibodies

B:-DGKE mutation

C:-MMACHC deletion

D:-CFI deletion

Correct Answer:- Option-A

Question52:-2-year-old male child was followed up in pediatric neurology OPD from 6 months of age for myoclonic seizures and progressed to develop ataxia, dysarthria, sensorimotor neuropathy. The child has now presented with generalized edema and kidney failure. He has 4+ proteinuria with estimated Glomerular filtration rate of 35 mL/min/1.73 m^2 . What is the most likely kidney biopsy finding in this syndromic association ?

A:-Minimal change disease

B:-Focal segmental glomerulosclerosis

C:-Mesangioproliferative glomerulonephritis

D:-Membranous nephropathy

Correct Answer:- Option-B

Question53:-5y/M presents with recurrent hematuria, progressive nephropathy and sensorineural deafness. Hemogram shows thrombocytopenia and giant platelets. On testing you find normal collagen 3, 4 and 5. What is your most likely diagnosis ?

A:-Alport syndrome

- B:-IgA nephropathy
- C:-Epstein syndrome
- D:-May-Hegglin anomaly

Correct Answer:-**Question Cancelled**

Question54:-All the following are components of Renal angina Index (RAI) except

- A:-ICU admission
- B:-Stem-cell transplant
- C:-Ventilation
- D:-Urine output

Correct Answer:- Option-D

Question55:-Kocher-Debre-Semelaigne syndrome is characterised with hypothyroidism along with which of the following ?

- A:-Pseudohypertrophy
- B:-Delayed milestones
- C:-Cerebral cysts
- D:-Myxedema

Correct Answer:- Option-A

Question56:-All the following are recently approved monoclonal antibodies for Asthma except

- A:-Omalizumab
- B:-Obinutuzumab
- C:-Depilumab
- D:-Resliumab

Correct Answer:- Option-B

Question57:-4-year-old girl brought with poor growth, increased thirst and urination for the past 2-3 years; she drinks ~3 L of water and urinates 10 times a day. Physical exam was unremarkable except chronic malnutrition Labs: Na 154 mEq/L, K 4.2 mEq/L, Ca 9.3 mg/dL, HCO₃ 23.2 mEq/L, glucose 89 mg/dL, TSH 1.35 mU/mL. Urinalysis: no proteinuria/glycosuria, specific gravity 1.002. USG revealed B/L hydroureteronephrosis. Which further test would you perform to confirm the diagnosis ?

- A:-Water deprivation test
- B:-GnRH stimulation test
- C:-Critical sample
- D:-Furosemide fludrocortisone test

Correct Answer:- Option-A

Question58:-Wolfram syndrome is characterised by all of the following except

- A:-Diabetes mellitus

B:-Diabetes Insipidus

C:-Neurodegeneration

D:-Thymus abnormalities

Correct Answer:- Option-D

Question59:-What is the most common cause of acquired hypothyroidism ?

A:-Thyroid dysgenesis

B:-Thyroid surgery

C:-Hashimoto thyroiditis

D:-Radiation therapy

Correct Answer:- Option-C

Question60:-15-year-old girl presented with primary amenorrhea. Breast development and pubic hair started developing 2.5 years back. No acne/hirsutism/chronic drug intake/surgery in the past. O/E - SMR stage 2, Genitalia-grossly normal female
Labs: TSH-3.7, FSH \uparrow , LH \uparrow , Estradiol \downarrow , AMH \downarrow , inhibin A \downarrow USG: Small uterus and streak ovaries, Karyotype-46 XY

A:-Swyer syndrome

B:-Congenital adrenal hyperplasia

C:-Smith-Lemli-Opitz syndrome

D:-Partial androgen insensitivity

Correct Answer:- Option-A

Question61:-Cerebral gigantism (Soto's syndrome) is characterised by following clinical features except

A:-Rapid growth due to endocrine dysfunction

B:-Bone age is almost similar to height age

C:-Dolichocephaly and large hands

D:-NSD1 epigenetic regulation

Correct Answer:- Option-A

Question62:-The following investigations aid in the diagnosis of Central precocious puberty except

A:-GnRH stimulation test causing LH peak >5 U/L in males

B:-GnRH stimulation test causing LH peak >5 U/L in females

C:-Leuprolide stimulation causing estradiol levels <50 pg/dL in males

D:-Leuprolide stimulation causing estradiol levels <50 pg/dL in females

Correct Answer:-**Question Cancelled**

Question63:-Hypoparathyroidism, sensorineural hearing loss and renal anomaly syndrome occurs due to the following gene pathogenic variants

A:-GATA3

B:-GNAS

C:-CaSR

D:-TBX1

Correct Answer:- Option-A

Question64:-Cushing syndrome is characterized by all the following except

A:-Midnight cortisol levels < 4.4 µg/dL

B:-Single dose dexamethasone suppression test with serum cortisol levels <5 µg/dL

C:-Elevated night time salivary cortisol

D:-Increased 24 hrs free urinary cortisol

Correct Answer:- Option-A

Question65:-What is the diagnostic yield of Exome Sequencing in Cerebral Palsy as per the recently published meta-analysis ?

A:-11-14%

B:-21-24%

C:-31-34%

D:-41-44%

Correct Answer:- Option-C

Question66:-A 8-month-old girl presents with extreme irritability and developmental regression. On examination, there is diffusely increased tone. CSF evaluation reveals increased protein. MRI shows Tigroid appearance. Which of the following tests would you perform for confirmation of the diagnosis ?

A:-Glucocerebrosidase

B:-Galactocerebrosidase

C:-Sphingomyelinase

D:-Alpha-mannosidase

Correct Answer:- Option-B

Question67:-Most likely cause of Multiphasic Acute disseminated encephalomyelitis (ADEM) is

A:-Aquaporin-4-antibody

B:-Aquaporin-2-antibody

C:-Aquaporin-6-antibody

D:-Myelin oligodendrocyte glycoprotein antibody

Correct Answer:- Option-D

Question68:-All the following epilepsy syndromes are most likely to begin in Infancy except

A:-West syndrome

B:-Dravet syndrome

C:-Progressive myoclonic epilepsy

D:-Benign Infantile seizures

Correct Answer:- Option-C

Question69:-All the following features are associated with Lafora body disease except

A:-Onset in adolescence

B:-Periodic acid-Schiff-positive inclusions

C:-Photosensitivity

D:-ARX mutations

Correct Answer:- Option-D

Question70:-Which of the following is a FDA approved, level A evidence supported antiepileptic for the treatment of childhood absence epilepsy ?

A:-Lamotrigine

B:-Valproate

C:-Ethosuximide

D:-Both 2 and 3

Correct Answer:- Option-D

Question71:-Childhood and Adolescent Migraine Prevention (CHAMP) study compared the efficacy of which of the following treatments for Migraine ?

A:-Topiramate and Amitriptyline

B:-Amitriptyline and Valproate

C:-Topiramate and Levetiracetam

D:-Flunarizine and Amitriptyline

Correct Answer:- Option-A

Question72:-A 5-year old boy presented with complains of progressive motor difficulties, personality changes, cognitive decline, dysarthria, spasticity and late onset dystonia; with "eye of the tiger" sign on MRI of brain. Which of the following is the most likely genetic mutation involved ?

A:-PRRT2

B:-PANK2

C:-HPRT

D:-ATXN7

Correct Answer:- Option-B

Question73:-White cerebellar sign is a radiological sign seen in all of the following except

A:-Hypoxic ischemic encephalopathy

B:-Posterior circulation stroke

C:-Head trauma

D:-Status epilepticus

Correct Answer:- Option-B

Question74:-5-year-old girl with progressive difficulty in walking, which worsens during the day and is better after night's sleep. The girl also has rigidity in the leg muscles and dystonic twisting of legs. Which of the following is the most likely drug of choice ?

A:-Levodopa

B:-Haloperidol

C:-Baclofen

D:-Neostigmine

Correct Answer:- Option-A

Question75:-All of the following are characteristic early manifestations of congenital syphilis except

A:-Hepatosplenomegaly and elevated liver enzymes

B:-Erythematous macular or vesiculo bullous lesions

C:-Multiple sites of osteochondritis causing pseudo paralysis

D:-Interstitial keratitis and 8th nerve deafness

Correct Answer:- Option-D

Question76:-Risk factors indicating increased probability of occult bacteremia include all of the following except

A:-Temperature $>39^{\circ}\text{C}$ (102.2°F)

B:-WBC Count $\geq 10,000/\mu\text{l}$

C:-Elevated absolute neutrophil count and band count

D:-Elevated CRP and/or ESR

Correct Answer:- Option-B

Question77:-Regarding the laboratory diagnosis of bacterial pathogen, which of the following statement is not true ?

A:-Sequence based identification of new bacteria is based on the sequence analysis of the bacterial 16S rRNA gene

B:-Refrigeration or urine transport devices with boric acid preservative may be used if there is some delay in transport of urine culture specimen

C:-Trichrome stain is used for identifying the bacteria

D:-Rapid antigen testing is a point of care testing for Group A streptococcus with false negative result up to 30%

Correct Answer:- Option-C

Question78:-A 6 month old child presented with recurrent infection in the skin, leading to a non-healing ulcer in the perianal area. He also gives a history of delayed cord separation. The complete blood count done in the local hospital showing a total WBC count of $90,000/\mu\text{l}$.

Functional absence of which CD marker is diagnostic ?

A:-CD18

B:-CD3

C:-CD19

D:-CD56

Correct Answer:- Option-A

Question79:-I am an antibiotic with the following characteristics

1. I will act by disrupts bacterial cell membrane function causing depolarization leading to

inhibition of protein, DNA and RNA synthesis, which results in bacterial cell death.

2. Active against enterococci, staphylococci, streptococci and corynbacteria.

3. Should not be used for pneumonia as drug inactivated by surfactant.

Identify the antibiotic :

A:-LORACARBEF

B:-LINEZOLID

C:-DAPTOMYCIN

D:-DEMECLOCYCLINE

Correct Answer:- Option-C

Question80:-As per the 2021 AWaRE classification under antibiotic stewardship programme, which of the antibiotic is not in the Access Category ?

A:-Amoxicillin/Claavulnic acid

B:-Azithromycin

C:-Cefazolin

D:-Clindamycin

Correct Answer:- Option-B

Question81:-Which of the following statements regarding Latent mycobacterial tuberculosis infection (LTBI) is correct ?

A:-Untreated infants with LTBI have upto 10% chance of development of tubercular disease

B:-Interferon gamma release assay (IGRA) is an advanced form of tuberculin skin test (TST)

C:-IGRA having an advantage of lack of cross reaction with BCG vaccination and most other mycobacteria

D:-IGRA positive LTBI in a 6 years old is treated with 6 month course of isoniazid as per the National/State guideline

Correct Answer:-**Question Cancelled**

Question82:-The commonest organism in any type of osteomyelitis

A:-Salmonella species

B:-Enterobacteriaceae

C:-Staphylococcus aureus

D:-Coagulase negative staphylococci

Correct Answer:- Option-C

Question83:-Which of the following statements about antinuclear antibody is correct ?

i. ANA as a screening test is not recommended for rheumatic disease since it is having low specificity.

ii. Up to 50% of children testing positive for ANAs have no underlying rheumatological conditions.

iii. A positive ANA test can be due to infection by parvovirus B19 infection.

A:-Only i and ii

B:-Only i and iii

C:-Only ii and iii

D:-All the statements i, ii and iii

Correct Answer:- Option-B

Question84:-Which is the IL-1 receptor antagonist (biological therapy) studied in patients with juvenile idiopathic arthritis (JRA) ?

A:-Rituximab

B:-Etanercept

C:-Anakinra

D:-Adalimumab

Correct Answer:- Option-C

Question85:-Which of the following statement is/are correct about haemoglobin ?

i. Large amount of Hb F is found in β thalassemia major.

ii. Levels of Hb_{A₂} > 3.0% are found in persons with β thalassemia trait.

iii. Decreased Hb_{A₂} levels are found in patients with iron deficiency anemia and α -thalassemia syndromes.

A:-Only ii and iii

B:-Only i and ii

C:-Only i and iii

D:-All of the above i, ii and iii

Correct Answer:- Option-D

Question86:-The causes of Microcytic anemia with low reticulocyte count include all of the following except

A:-Iron deficiency anemia

B:-Copper deficiency

C:-Iron refractory Iron deficiency anemia

D:-Haemoglobin C and E disorders

Correct Answer:- Option-D

Question87:-Which of the following statement is true regarding Iron ?

A:-Breast milk has higher iron content than cow's milk

B:-Cow's milk has higher oral bioavailability of iron than breast milk

C:-Introduction of Cow's milk at 5 months of age decreases the risk of iron deficiency

D:-Cow's milk protein can cause chronic intestinal blood loss in infants

Correct Answer:- Option-D

Question88:-Which of the following is the predominant site of hematopoiesis in a 20 week old fetus ?

A:-Yolk sac

B:-Liver

C:-Spleen

D:-Bone marrow

Correct Answer:- Option-B

Question89:-You are performing the tuning fork test on a patient who presented to the OPD with the complaints of decreased hearing in the left ear. Which of the following tuning forks is most commonly used for the clinical assessment of that patient ?

A:-128

B:-256

C:-512

D:-1024

Correct Answer:- Option-C

Question90:-Which of the following statement is not a characteristic feature of shwachman Diamond Syndrome ?

A:-Most patients have symptoms of protein malabsorption

B:-Bacterial and fungal infection are common secondary to neutropenia

C:-The wild type gene product is involved in ribosomal biogenesis

D:-Only curative management is Haemopoetic stem cell transplant

Correct Answer:- Option-A

Question91:-Which of the following statement regarding Von Williebrands disease (vWD) is correct ?

i. Platelet count is low in vWD Type 2B.

ii. Desmopressin is used in all types of vWD.

iii. Circulating factor VIII activity is low in vWD Type 2N.

A:-Only ii and iii

B:-Only i and iii

C:-Only i and ii

D:-All statements i, ii and iii

Correct Answer:- Option-B

Question92:-Hereditary deficiency of platelet storage granules occurs in

A:-Glanzmann thrombasthenia

B:-Bernard Soulier syndrome

C:-Wiskot Aldrich syndrome

D:-Gray platelet syndrome

Correct Answer:- Option-D

Question93:-All of the following are diagnostic tests for the establishing splenic dysfunction except

A:-Technetium -99m- labelled Sulphur colloid scintiscan

B:-Detection of Howell-Jolly bodies by staining

C:-Flow cytometric EMA (eosin 5 maleimide) binding test

D:-Detection of pitted erythrocytes by phase-interference microscopy (more than 4%)

Correct Answer:- Option-C

Question94:-Which of the following feature is incorrectly matched in a otoscope finding of acute otitis media without perforation ?

A:-Position - Full to bulging

B:-Color - Red (can be pink or white or yellow)

C:-Translucency - opaque

D:-Mobility - None

Correct Answer:- Option-D

Question95:-Syndromic causes of autosomal dominant Sensorineural hearing loss (SNHL) causes include all of the following except

A:-Usher Syndrome

B:-Wardenberg syndrome

C:-Brachiootorenal syndrome

D:-CHARGE syndrome

Correct Answer:- Option-A

Question96:-Which of the following statements regarding Refractive error in children are correct ?

i. Myopia is infrequent in infants whereas incidence increases during the school years.

ii. Myopia is more common in infants with a history of retinopathy of prematurity.

iii. Convex lens of appropriate strength to provide clear vision is used as the treatment of

choice of Myopia.

A:-i and ii

B:-i and iii

C:-ii and iii

D:-i, ii and iii

Correct Answer:- Option-D

Question97:- Amaurotic cat's eye reflex is seen in all of the following conditions except

A:-Peters anomaly

B:-Coats exudative retinopathy

C:-Retinoblastoma

D:-Cicatrical retinopathy of prematurity

Correct Answer:- Option-A

Question98:- Identify the wrong match in related to drug eruptions in Pediatric patients

A:-DRESS Syndrome - Pencillamine

B:-Steven Johnson syndrome - Carbamazepine

C:-Fixed drug eruption - Sulfonamides

D:-Drug induced lupus - Procainamide

Correct Answer:- **Question Cancelled**

Question99:- Which of the following statements regarding scabies is correct ?

i. Even though burrows are characteristic lesions of scabies, in infants and children bullae and

pustules are relatively common.

ii. The treatment of choice of scabies is permethrin cream 10% for local application.

iii. In immunocompromised children Ivermectin can be given at a dose of 200 µg/kg per dose

orally for 2 doses.

A:-i and ii

B:-i and iii

C:-ii and iii

D:-i, ii and iii

Correct Answer:- Option-B

Question100:- A "reverse" Ponsetti method of serial casting is recommended in the management of which condition ?

A:-Calcaneovalgus feet

B:-Metatarsus adductus

C:-Congenital vertical talus

D:-Talipes Equinovarus

Correct Answer:- Option-C